



**RESENTING CLINICAL SIGNS**

History: Grade 2/6 murmur. Coughing – suspect tracheobronchitis. Pre-anesthetic evaluation (mass removal). Receiving Benadryl, doxycycline, and Apoquel.

DATE

10/1/21

**ECHOCARDIOGRAPHIC FINDINGS**

2D, M-mode, and Doppler study.

PERFORMED BY:

Shari Reffi, CVT

INTERPRETED BY

Keith Blass, DVM,  
MS, DACVIM  
(Cardiology)

Left atrial size is normal. The mitral valve appears normal, though trace mitral regurgitation is present. Left ventricular dimensions are normal, as is left ventricular systolic function. The aorta and aortic valve appear normal, though there is mildly increased flow velocity in the ascending aorta. Right atrial and right ventricular dimensions are normal. The tricuspid valve is normal. The pulmonary artery and pulmonic valve are normal. No pericardial effusion or cardiac masses are seen.

PATIENT

Mason Forgiore

LA – 39.2 mm  
LVIDd – 34.5 mm  
LVIDs – 21.0 mm  
FS – 39%  
RA – 30.6 mm  
LVOT – 1.59 m/s  
RVOT – 1.20 m/s

**ASSESSMENT/RECOMMENDATIONS**

SPECIES

Canine

This examination demonstrates no evidence of structural heart disease, as trace mitral regurgitation can be considered a normal physiologic variant. Mason’s murmur appears to be due to the presence of mildly increased flow velocity in his aorta, which is a common reason for a functional/innocent murmur to develop in boxers.

BREED

Boxer

Mason’s cardiovascular risk for general anesthesia is low based on this exam, and there are no contraindications to the use of any specific anesthetic agents.

SEX

No therapy is recommended based on this exam.

MN

A recheck echocardiogram is recommended if the characteristics of Mason’s murmur change, or if other new physical exam and/or clinical abnormalities suggestive of cardiac dysfunction develop.

AGE

8 y

WEIGHT

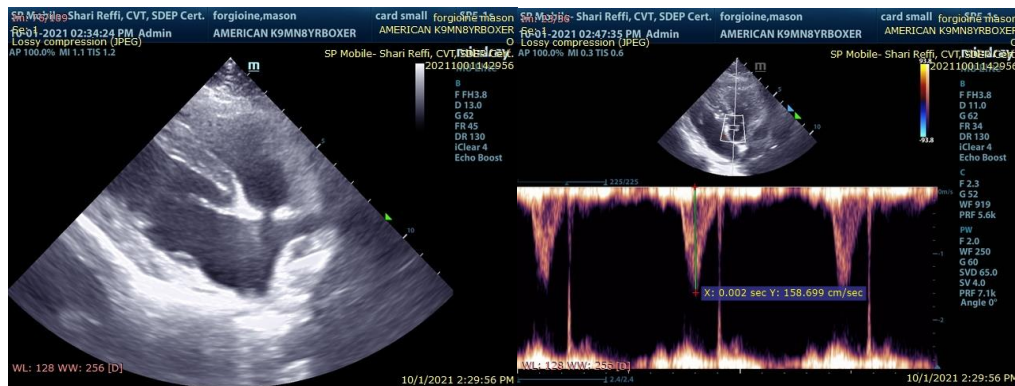
69.7 lb

HOSPITAL NAME

American AH

REFERRING VET

Dr. Stockmal





The information and recommendations provided are based on the images presented by the referring veterinarian. No evaluation can be communicated regarding pathology that was not visible in the image/video clips provided.

**DATE**

10/1/21

Thank you for this referral. If the clinical or image interpretation does not parallel your findings or if I can be of any further assistance please contact me.

**PERFORMED BY:**

Shari Reffi, CVT

**Keith Blass, DVM, MS, DACVIM (Cardiology)**  
KeithBlass@gmail.com  
631-804-5754

**INTERPRETED BY**

Keith Blass, DVM,  
MS, DACVIM  
(Cardiology)

**PATIENT**

Mason Forgione

**SPECIES**

Canine

**BREED**

Boxer

**SEX**

MN

**AGE**

8 y

**WEIGHT**

69.7 lb

**HOSPITAL NAME**

American AH

**REFERRING VET**

Dr. Stockmal